



## Oration

# Hypertrophic cardiomyopathy: The first century 1869–1969

Eugene Braunwald\*

Brigham and Women's Hospital,  
Harvard University, Boston MA, USA  
\*Email: ebraunwald@partners.org

Thank you so much, Professor Yacoub. It's a great honor for me to participate in this conference. I thank you for your vision and your tremendous energy and for everything that you have and are and will accomplish in cardiovascular surgery and science.

I'm going to talk about the first century of hypertrophic cardiomyopathy (HCM) and will emphasize my experience during the last decades of this century.

Few people realize that the first patient with HCM was described in 1869, during the reign of Queen Victoria. The great physician, William Osler, was four years old. Winston Churchill had not yet been born. The electrocardiogram and cardiac catheterization were 35 and 60 years in the future, respectively. But, in the *Medical Gazette of Paris*, a paper appeared, which was entitled *Cardiac Sub-Aortic Stenosis* by Henri Liouville [1] and which described a 75-year-old woman who developed worsening dyspnea over several days. On physical examination, she had a systolic heart murmur. She died shortly after presentation. An autopsy revealed the following:

*"The left ventricle is enlarged and very thick. It has considerable concentric hypertrophy"—*which means that Liouville understood the difference between concentric and eccentric hypertrophy—*"measuring 3.5 to 4 centimeters in width. When I insert my index finger from the ventricle toward the aortic outflow tract, my finger becomes tightly pinched in the myocardium, one centimeter below the aortic valve. The aortic valve itself does not appear to be stenosed or calcified. When I try to insert my thumb backward through the aortic valve toward the ventricle, it cannot reach my index finger that I have inserted from the opposite direction. This is due to the obstruction that is caused by the myocardial thickening that is situated below the level of the aortic valve. There is no evidence of aortic insufficiency by water testing."*

I think that this case report is incredible for the time. This physician examined the patient, recognized and timed the murmur, and after her death described carefully the pathology that all of us now recognize as HCM.

Now, I call your attention to a paper published in the *Deutsche Med. Wochenschrift* in 1907 [2]. The paper is about left-sided muscular outflow tract obstruction by a pathologist, Dr. A. Schmincke. He described two hearts, both of which came from women in their mid fifties. They both had left ventricular hypertrophy. Decades before the development of left heart catheterization, Schmincke described a vicious circle as follows:

*"Diffuse muscular hypertrophy of the left ventricle outflow tract causes an obstruction. The left ventricle has to work harder to overcome the obstruction. So, the primary hypertrophy will be accompanied by a secondary hypertrophy causing an incremental (further) narrowing of the outflow tract."* He clearly understood that hypertrophy caused obstruction to left ventricular outflow which in turn caused more hypertrophy.

Now that I have mentioned these two remarkable very early papers, I want to turn to the more recent observations which have led to our current understanding of the clinical and hemodynamic features of HCM. There are six major components.

## VENTRICULAR HYPERTROPHY

A key paper, published in 1944, was entitled: *Cardiac Hypertrophy of Unknown Cause. A study of the clinical and pathologic features in ten adults*, by Levy, a clinician, and Von Glahn, a pathologist, both at Columbia University in New York [3]. They wrote presciently:

[http://dx.doi.org/  
10.5339/gcsp.2012.5](http://dx.doi.org/10.5339/gcsp.2012.5)

Published: 6 September 2012  
© 2012 Braunwald, licensee  
Bloomsbury Qatar Foundation  
Journals. This is an open access  
article distributed under the terms  
of the Creative Commons  
Attribution-NonCommercial license  
CC BY-NC 3.0 which permits  
unrestricted non-commercial use,  
distribution and reproduction in  
any medium, provided the original  
work is properly cited.

*“These cases appear to form a clinical group of which the chief features are: marked cardiac hypertrophy, symptoms of cardiac insufficiency and occurrence of various types of arrhythmia. The hearts, at autopsy, all show hypertrophy of the muscle fibers; in others, there is also fibrosis. . . Whether these cases represent a single disease, observed at different stages of its development, or are to be regarded as of heterogeneous origin, cannot now be stated.”*

### **FAMILIAL**

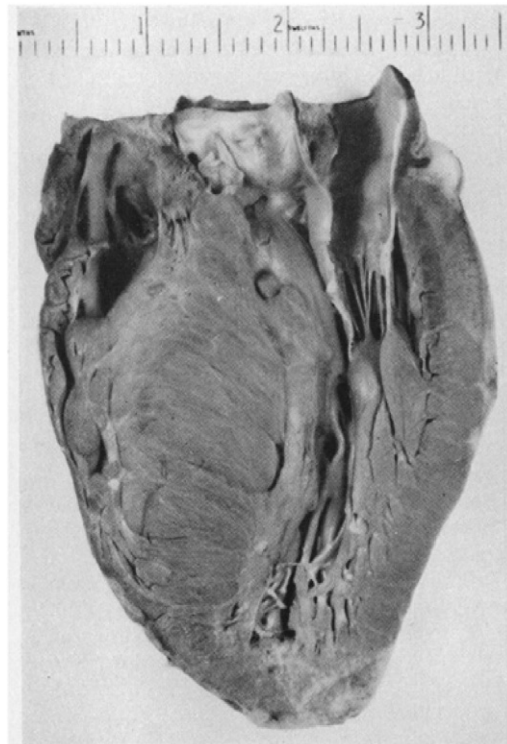
In 1949, William Evans [4], a London cardiologist, described patients with cardiac hypertrophy who were very similar to those described in the paper by Levy and von Glahn [3] except for its familial occurrence. He wrote:

*“There is described in this paper a distinct syndrome having a definite clinical, cardiographic and pathological pattern . . . having regard to the specificity of the condition and its chief characteristics I propose to name it Familial Cardiomegaly.”*

This was followed by a remarkable paper by Paré et al. published in 1961 [5]. It includes 30 members of five generations of a French Canadian family residing in Quebec in whom the condition was inherited in an autosomal dominant manner.

### **SUDDEN CARDIAC DEATH**

A very important characteristic of HCM was described in 1958 by Teare, a London pathologist [6]. He described eight cases of hypertrophy which were so asymmetric that he thought that they might be benign cardiac tumors (Fig. 1). Seven of these caused sudden death in young adults. The pathological picture was one of bizarre and disorganized muscle bundles associated with hypertrophy of individual muscle fibers and their nuclei. Teare named the condition “Asymetrical Hypertrophy of the Heart.”



**Figure 1.** Gross anatomy of the heart in a patient with familial HCM (Ref. [6]).

### **LEFT VENTRICULAR OUTFLOW TRACT OBSTRUCTION**

In 1958, I was head of the cardiac catheterization laboratory at the National Heart Institute in Bethesda, Maryland, where I worked closely with Andrew Glenn Morrow who was chief of cardiac surgery. It was in the very early days of open-heart surgery, which was a very complicated, risky procedure at the time.

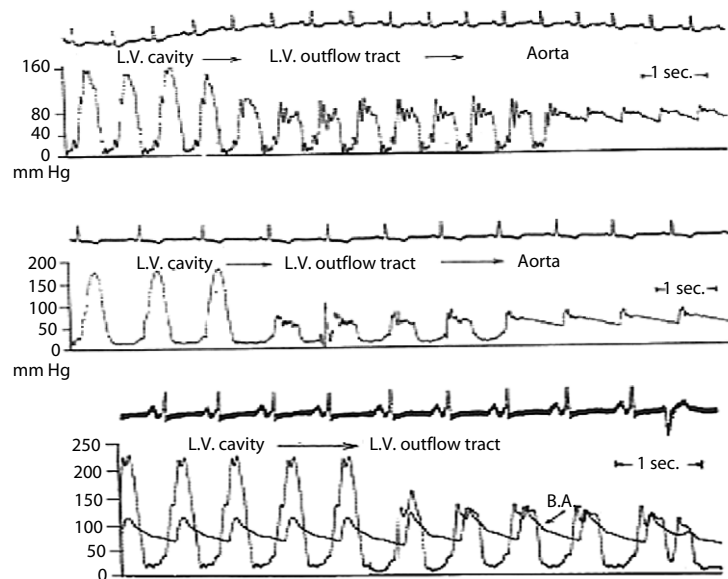
We studied a young man of about 22 years with angina and dyspnea who had a high subaortic pressure gradient. We assumed that he had a congenital membranous subaortic stenosis, and that he was a good candidate for surgery. During surgery, I received a call from Dr. Morrow's nurse, who said that Dr. Morrow wanted me to come to the operating room immediately. When I arrived, he was agitated and said that there was no obstruction in the patient's left ventricle! The heart had been arrested with potassium citrate, and he had performed an aortotomy. He had inserted his finger into the outflow tract of the left ventricle and found no obstruction. He then inserted his other index finger through the left atrium into the left ventricular cavity where his fingers met. While we had no idea what caused the intraventricular pressure gradient, Morrow did appreciate that there was considerable left ventricular hypertrophy. The young man recovered uneventfully from the procedure. Several weeks later we encountered a second patient with almost identical findings [7].

At about the same time, Sir Russell Brock, the leading cardiovascular surgeon in the United Kingdom at the time, described a 32-year-old man with angina pectoris and a heart murmur of subaortic stenosis. He too exhibited a subaortic intraventricular pressure gradient [8]. In his report, Brock stated:

*"That this is not an isolated case is made clear by the experience of Dr. Glenn Morrow who tells me he has operated on two similar cases in two young men in their early twenties; both survived. He has kindly allowed me to mention these prior to his own report of them (Morrow and Braunwald, Circulation, in press, 1959)."*

These two papers [7,8] were published virtually simultaneously. And I think that it was the development of open-heart surgery that really put hypertrophic obstructive cardiomyopathy (HOCM) on the map.

In 1960, we described three siblings who demonstrated three of the abovementioned cardinal features: left ventricular hypertrophy, familial association, and hemodynamic changes of left ventricular outflow tract obstruction (Fig. 2).



**Figure 2.** Left heart dynamics in three siblings with obstructive HCM. LV = left ventricular (Ref. [9]).

### DYNAMIC OBSTRUCTION

The fifth feature is the dynamic nature of the obstruction. We observed that physiologic and pharmacologic interventions that alter the size of the ventricle and its contractility affect the presence and severity of obstruction. We observed that in patients with HCM but without an intraventricular pressure gradient, the obstruction can be provoked, or, if present, can be intensified with an infusion of isoproterenol, which by its combined inotropic and vasodilator actions reduces the size of the left ventricular tract and thereby intensifies the obstruction (Fig. 3). Nitroglycerine, by reducing ventricular filling, has a similar action (Fig. 4).

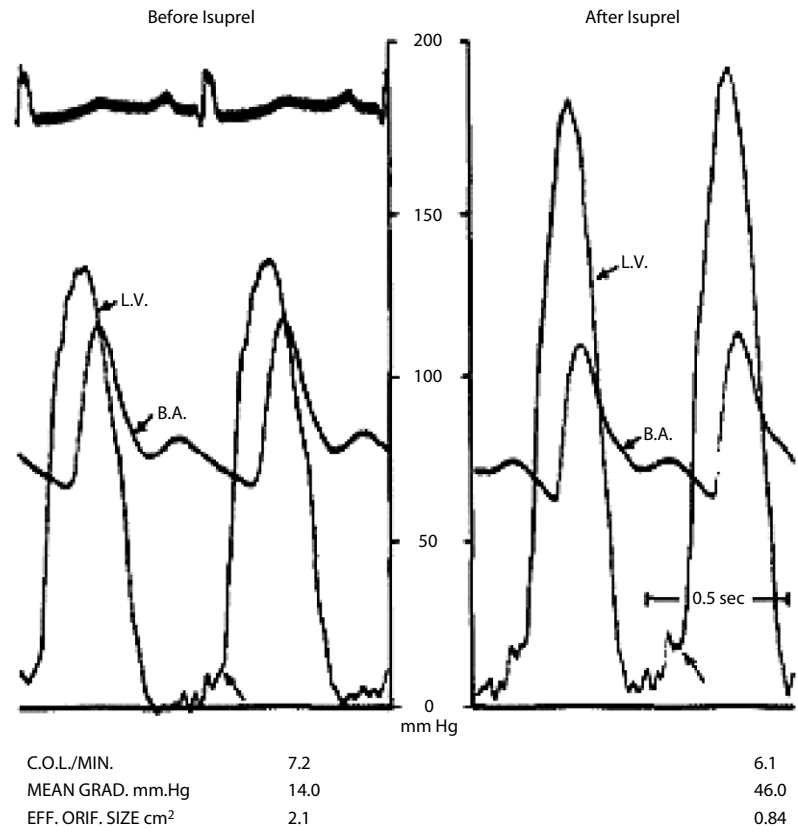


Figure 3. Hemodynamic effects of 2 µg isoproterenol. Isuprel = isoproterenol, C.O. = cardiac output, Grad. = gradient, Eff. Orif. = effective orifice (Ref. [10]).

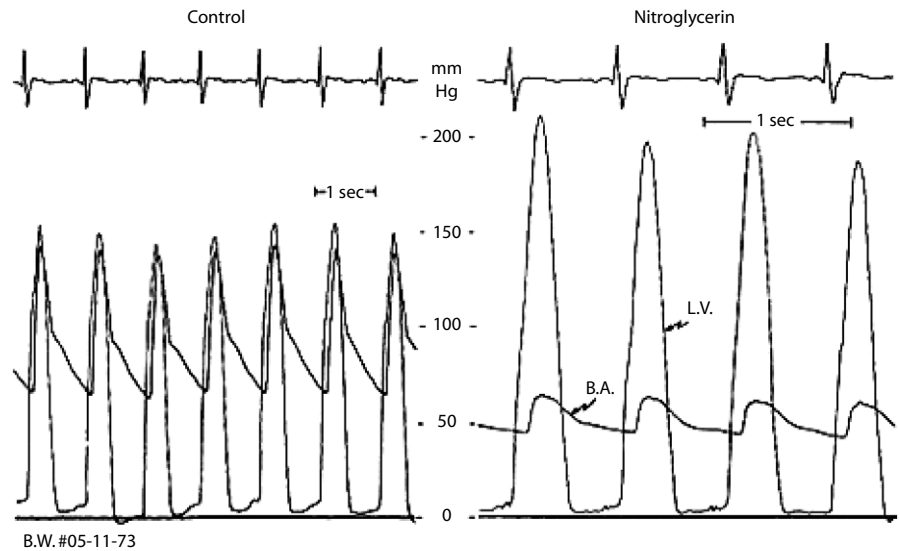


Figure 4. Circulatory response to nitroglycerin in patient B.W. with HCM. LV, left ventricular pressure pulse; BA, brachial arterial pressure pulse. (From Braunwald E, Oldham H N Jr, Ross J Jr, et al. The circulatory response of patients with idiopathic hypertrophic subaortic stenosis to nitroglycerin and to the Valsalva maneuver. *Circulation* 1964;29:422-431).

### TREATMENT

In 1961, Morrow described a surgical procedure to relieve the obstruction [11].

He incised the greatly hypertrophied interventricular septum (cardiac myotomy) and then excised some tissue in the left ventricular outflow tract (cardiac myectomy). Substantial clinical and hemodynamic benefit was observed [12].

In addition to surgical treatment we also thought about medical treatment. Given the intensification of obstruction with the beta-adrenergic agonist isoproterenol [10], we considered the use of newly developed beta-blockers. In 1964 we reported their beneficial hemodynamic effects [13] and later the clinical benefits that they achieved [14]. It is gratifying that a half century after these therapies were described, beta-blockers remain the first-line pharmacologic treatment for HCM with outflow tract obstruction while the myotomy-myectomy procedure described by Morrow is the most widely used intervention.

So I will end by pointing out that the first century was a very fascinating period in the history of HCM [15]. This condition was once considered to be very rare, but it is now recognized to occur once in every 2500 births, and is the most frequently occurring monogenic cardiac disorder [16].

*Edited transcript of a speech given at the Aswan Heart Centre Science and Practice Series meeting, 3–6th January 2011, Cairo, Egypt.*

#### References

- [1] Liouville H. Rétrécissement cardiaque sous aortique. Gazette Medecine Paris. 1869;24:161–163.
- [2] Schmincke A. Ueber linkseitige muskulöse conustenosen. Deutsche Med Wochenschr. 1907;33:2082–2085.
- [3] Levy RL and von Glahn WC. Cardiac hypertrophy of unknown cause. A study of the clinical and pathologic features in ten adults. Am Heart J. 1944;28:714–741.
- [4] Evans W. Familial cardiomegaly. Br Heart J. 1949;11:68–82.
- [5] Paré JAP, Fraser RG, Pirozynski WJ, Shanks JA and Stubington D. Hereditary cardiovascular dysplasia. A form of familial cardiomyopathy. Am J Med. 1961;31:37–62.
- [6] Teare D. Asymmetrical hypertrophy of the heart in young adults. Br Heart J. 1958;20:1–8.
- [7] Morrow AG and Braunwald E. Functional aortic stenosis: A malformation characterized by resistance to left ventricular outflow without anatomic obstruction. Circulation. 1959;20:181–189.
- [8] Brock R. Functional obstruction of the left ventricle (acquired aortic subvalvar stenosis). Guy's Hosp Rep. 1959;108:126–43.
- [9] Braunwald E, Morrow AG, Cornell WP, Aygen MM and Hilbish TF. Idiopathic hypertrophic subaortic stenosis: Clinical, hemodynamic and angiographic manifestations. Am J Med. 1960;29:924–945.
- [10] Braunwald E and Ebert PA. Hemodynamic alterations in idiopathic subaortic stenosis induced by sympathomimetic drugs. Am J Cardiol. 1962;10:489–495.
- [11] Morrow AG and Brockenbrough EC. Surgical treatment of idiopathic hypertrophic subaortic stenosis. Technic and hemodynamic results of subaortic ventriculomyotomy. Ann Surg. 1961;154:181–189.
- [12] Morrow AG, Lambrew CT and Braunwald E. Idiopathic hypertrophic subaortic stenosis. II. Operative treatment and the results of pre and postoperative hemodynamic evaluations. Circulation. 1964;30:Suppl 4, 120–151.
- [13] Harrison DC, Braunwald E, Glick G, Mason DT, Chidsey CA and Ross J Jr. Effects of beta-adrenergic blockade on the circulation with particular reference to observations in patients with hypertrophic subaortic stenosis. Circulation. 1964;29:84–98.
- [14] Cohen LS and Braunwald E. Amelioration of angina pectoris in idiopathic hypertrophic subaortic stenosis with beta-adrenergic blockade. Circulation. 1967;35:847–851.
- [15] Braunwald E. Hypertrophic cardiomyopathy: The early years. J Cardiovasc Trans Res. 2009;2:341–348.
- [16] Maron BJ and Braunwald E. Eugene Braunwald, M.D. and the early years of hypertrophic cardiomyopathy: A conversation with Dr. Barry J. Maron. Am J Cardiol. 2012;109:1539–47. epub Mar 15.