



JEMTAC

Journal of Emergency Medicine
Trauma & Acute Care
A PEER REVIEWED JOURNAL

OPEN ACCESS

Case study

Avulsion of the right main bronchus due to blunt trauma

Majdi Ibrahim, Hasan Sandogji, Abdallah Allam

ABSTRACT

Tracheobronchial disruption is an uncommon injury usually associated with severe blunt thoracic trauma. It rarely occurs in isolation. We report a case of isolated avulsion of the right main bronchus occurring after a high-speed car collision with severe head injury. Management of this condition is briefly discussed.

Keywords: bronchus, surgical emphysema, avulsion, trauma

Department of Thoracic Surgery, King Fahad Hospital, Almadinah Almunawarah, Saudi Arabia
Email: magdi.wahdan@gmail.com, drhsand@hotmail.com, aallam33@hotmail.com

<http://dx.doi.org/10.5339/jemtac.2012.5>

Published: 10 May 2012
© 2012 Ibrahim et al, licensee Bloomsbury Qatar Foundation Journals. This is an open access article distributed under the terms of the Creative Commons Attribution License CC BY 3.0 which permits unrestricted use, distribution and reproduction in any medium, provided the original work is properly cited.

INTRODUCTION

The incidence of tracheobronchial disruption after blunt chest trauma is low, and most patients with this type of injury do not survive to reach hospital care [1–5]. The clinical presentation is variable depending on the presence of associated injuries and on whether the peribronchial tissues remain intact [2–4].

A high index of clinical suspicion and accurate interpretation of radiological findings are necessary to diagnose the injury at presentation and allow prompt surgical intervention with primary repair of the airway. Delays in treatment increase the risk of mortality and of delayed partial or complete bronchial stenosis [6–8].

CASE REPORT

A 22 year-old male was admitted to the King Fahad Hospital following a high-speed car collision. Following the accident he was unconscious due to severe head trauma. On admission, he was unstable hemodynamically with hypoxia and hypercapnia. Clinical examination of the chest showed some anterior chest wall bruising and decreased air entry on the right side. A chest radiograph showed a surgical emphysema and right pneumothorax. Dynamic computer tomographic (CT) scanning was then performed and showed no evidence of vascular injury but there was rupture of right main bronchus with complete collapse of right lung (Fig. 1).

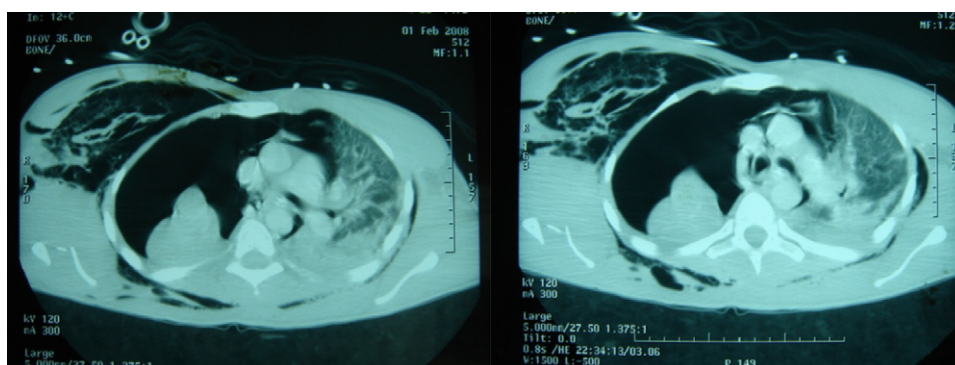


Figure 1. CT scan: rupture of right main bronchus with complete collapse of right lung, right surgical emphysema and pneumomediastinum.

The patient was admitted to the intensive care unit where he was intubated and connected to mechanical ventilation. An intercostal tube was inserted and a massive air leak observed. The patient was arrested but successfully resuscitated and transferred to the operative theatre where he arrested again but was successfully resuscitated. A double lumen tube was inserted immediately to ventilate the left lung. He then underwent a right postero-lateral thoracotomy through the fifth intercostal space. This confirmed complete separation of the right main bronchus just below the carina. A primary repair with interrupted 4-0 polyglactin (Vicryl) was performed after mobilizing the transected airway without disruption of the blood supply. A pleural patch was placed over the anastomotic site. To prevent airway dehiscence and fistula, every procedure was meticulously performed and a pleural flap was employed. A watertight seal of the anastomotic region was confirmed after the operation.

Immediate postoperative flexible bronchoscopy revealed successful repair. Chest x-ray was done immediately postoperative showing complete inflation of the right lung (Fig. 2). The patient was in a coma due to severe head trauma for about three weeks. Then the patient was gradually recovered from coma and discharged from hospital in good general condition. The patient has remained well at over 6 months postoperative (Fig. 3).

DISCUSSION

The first reported case of traumatic ruptured bronchus is attributed to Webb in 1848 following a postmortem on a man run over by a cart [13]. Primary surgical repair was first successfully performed by Scannell in 1951 [14]. Tracheobronchial disruption is an uncommon but life threatening injury associated with blunt thoracic trauma. The estimated incidence of tracheobronchial disruption obtained from clinical series was 2.9–5.8% [9,15], and the incidence within the pediatric group is

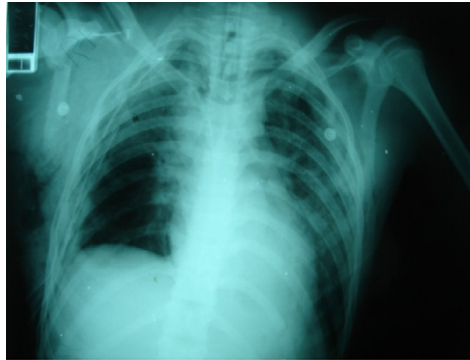

Figure 2. Immediate post-op. chest X-ray.

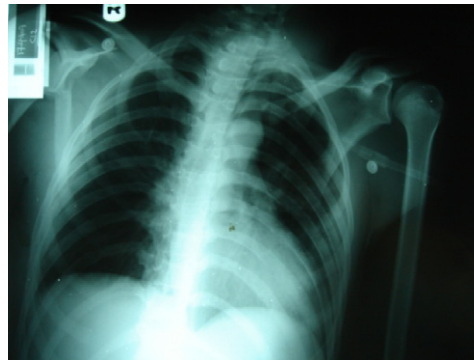


Figure 3. Six months post-op. chest X-ray.

0.7–2.8% [16]. Though the incidence is low, tracheobronchial disruption has a high potential for rapid progression to death. The mortality rate may be up to 30%. Half of the children with tracheo-bronchial disruption died within one hour of the traumatic event [10].

The pathogenesis of tracheobronchial disruption may be divided into three mechanisms, which may act alone or in concert [3]. The first is the decrease in the antero-posterior diameter of the thorax, which may cause traction of the carina and disruption of the tracheobronchial tree. The second is when the trachea and major bronchi are crushed between the sternum and vertebral column with glottis closed may lead to bronchial rupture, especially in membranous parts [16]. The third is rapid deceleration which leads to shearing force at the areas of fixation, namely the carina and cricoid cartilage. We believed that one or a combination of mechanisms were the main etiologies of this case.

The initial clinical presentations [3,4,17] are subcutaneous emphysema (85%) and dyspnea (77%). Other clinical manifestations include persistent large air leaks, pneumothorax, massive atelectasis, and failure to expand the lung with thoracostomy tube drainage [5]. According to X-ray findings, Mordehai et al. considered that pneumomediastinum and cervical emphysema were the highest sensitivity markers of airway rupture [18]. In addition, decreased upper lung margin below the level of bifurcation (fallen lung sign) is regarded as a typical sign for a complete disruption of the main bronchus [15,17]. All those presented in our patient and were highly suggestive of major tracheobronchial injury. Cay et al. considered that the presence of “deep neck emphysema” was the main indication for prompt bronchoscopy [4]. It was the most reliable means of establishing the diagnosis, and determining the site, nature, and the extent of tracheobronchial disruption [11,16,17,19].

Successful treatment of a tracheobronchial disruption includes prompt diagnosis, early airway repair under appropriate surgical approach, good anesthesia techniques, and the best operative techniques. Rupprecht et al. reported that reconstruction of the tracheo-bronchial tree within the first 24 h showed no degree of later pulmonary dysfunction. On the other hand, late reconstruction was associated with a decrease between 30 and 50% of vital and 80% of diffuse capacity [17].

The best surgical approach for tracheobronchial disruption is postero-lateral thoracotomy [20]. Using this approach, the surgeon can access the carina and main bronchus at its origin. Relating to

anesthesia technique, intubation with a double-lumen tube is the most common and comfortable method to ventilate the contralateral lung without air leaks during bronchial reconstruction in adult patients according to the patient's age and body weight [12,21]. In our patient, a postero-lateral thoracotomy was performed via the fifth intercostal space after intubation with a double-lumen tube.

The optimal surgical procedure for tracheobronchial disruption is debridement of injured tissue and end-to-end anastomosis [5,15,16] Grillo et al. recommended the importance of the preservation of tracheal and bronchial blood supply and the limitation of tension while repairing tracheobronchial disruption [22]. In our patient, we used monofilament absorbable interrupted sutures to repair the bronchus in order to avoid granuloma and airway stenosis [1,23]. During a post-operative follow up, we found good airway pattern without stricture over the anastomotic region.

In conclusion, bronchial avulsion is an unusual complication of blunt chest trauma, and the diagnosis can be delayed unless the treating medical staff has a high index of clinical suspicion in addition to the correct interpretation of clinical and radiological findings. Where the diagnosis is suspected, bronchoscopy should be performed in a fully equipped operating theatre in close cooperation with anesthetic staff, thus enabling orderly progression to thoracotomy and primary surgical repair to minimize the morbidity and mortality of such injuries.

References

- [1] Holmes J.F., Sokolove P.E., Brant W.E. and Kuppermann N. A clinical decision rule for identifying children with thoracic injuries after blunt torso trauma. *Ann Emerg Med.* 2002;39, 492–499.
- [2] Grant W.J., Meyers R.L., Jaffe R.L. and Johnson D.G. Tracheobronchial injuries after blunt chest trauma in children—hidden pathology. *J Pediatr Surg.* 1998;33:1707–1711.
- [3] Baumgartner F., Sheppard B., de Virgilio C., Esrig B., Harrier D., Nelson R.J. and Robertson J.M. Tracheal and main bronchial disruptions after blunt chest trauma: presentation and management. *Ann Thorac Surg.* 1990;50:569–574.
- [4] Cay A., Imamoglu M., Sarihan H., Kosucu P. and Bektas D. Tracheobronchial rupture due to blunt trauma in children: report of two cases. *Eur J Pediatr Surg.* 2002;12:419–422.
- [5] Massard G., Wihlm J.M., Roeslin N., Dumont P., Witz J.P. and Morand G. Emergency repair of main stem bronchus disruption complicated by anastomotic stenosis: two cases of successful repair by resection and reanastomosis. *J Trauma.* 1991;31:1569–1571.
- [6] Baumgartner F., Sheppard B., de Virgilio C. et al. Tracheal and main bronchial disruptions after blunt chest trauma: Presentation and management. *Ann Thor Surg.* 1990;50:569–574.
- [7] Roxburg J.C. Rupture of the tracheobronchial tree. *Thorax.* 1987;42:681–688.
- [8] Mills S.A., Johnstone F.R., Hudspeth A.S. et al. Clinical spectrum of blunt tracheo-bronchial disruption illustrated by 7 cases. *J Thorac Cardiovasc Surg.* 1982;84:49–57.
- [9] Kemmerer W.T., Echert W.G., Gathright J.B. et al. Patterns of thoracic injuries in fatal traffic accidents. *J Trauma.* 1961;1:595–599.
- [10] Juttner F.M., Pinter H., Popper H., Ratschek M. and Friehs G.B. Reconstructive surgery for tracheobronchial injuries including complete disruption of the right main bronchus. *Thorac Cardiovasc Surg.* 1984;32:174–177.
- [11] Jones W.S., Mavroudis C., Richardson D.J. et al. Management of tracheobronchial disruption resulting from blunt trauma. *Surgery.* 1984;95:319–323.
- [12] Deslauriers J., Bealieu M., Archambault G. et al. Diagnosis and long term follow up of major bronchial disruptions due to nonpenetrating trauma. *Ann Thorac Surg.* 1982;33:32–39.
- [13] Webb A. *Pathologica Indica or the Anatomy of the Indian Disease.* 2nd ed., Thacker, Calcutta. 1848.
- [14] Scannell J.G. Rupture of the bronchus following closed injury to the chest. *Ann Surgery.* 1951;133:127–130.
- [15] Singh N., Narasimhan K.L., Rao K.L. and Katariya S. Bronchial disruption after blunt trauma chest. *J Trauma.* 1999;46:962–964.
- [16] Sirbu H., Herse B., Schorn B., Huttemann U. and Dalichau H. Successful surgery after complete disruption of the right bronchial system. *J Thorac Cardiovasc Surg.* 1995;43:239–241.
- [17] Rupperecht H., Rumenapf G., Petermann H. and Gunther K. Transthoracic bronchial intubation in a case of main bronchus disruption. *J Trauma.* 1996;41:895–898.
- [18] Mordehai J., Kurzbar E., Kappler V. and Mares A.J. Tracheal rupture after blunt chest trauma in a child. *J Pediatric Surg.* 1997;32:104–105.
- [19] Singh N., Narasimhan K.L., Rao K.L. and Katariya S. Bronchial disruption after blunt trauma chest. *J Trauma.* 1999;46:962–964.
- [20] Marzelle J., Nottin R., Dartevelle P., Gayet F.L., Navajas M. and Rojas Miranda A. Combined ascending aorta rupture and left main bronchus disruption from blunt chest trauma. *Ann Thorac Surg.* 1989;47:769–771.
- [21] Oh A.Y., Kwon W.K., Kim K.O., Kim H.S. and Kim C.S. Single-lung ventilation with a cuffed endotracheal tube in a child with a left mainstem bronchus disruption. *Anesth Analg.* 2003;96:696–697.
- [22] Grillo H.C., Mathisen D.J. and Wain J.C. Laryngeal resection and reconstruction for subglottic stenosis. *Ann Thorac Surg.* 1992;53:54–63.
- [23] Ishikawa S., Onizuka M., Matsumaru Y., Yamada T., Tsukada A., Mitsui K. and Hori M. Successful reconstruction for combined tracheal and bronchial disruption. *Ann Thorac Surg.* 1993;56:160–161.