



Management of benign paroxysmal positional vertigo (BPPV) in the emergency department

Khalid Bashir^{1,2,*}, Furqan Irfan¹, Peter A Cameron¹

ABSTRACT

Benign paroxysmal positional vertigo (BPPV) is a common medical condition that can be managed by emergency physicians. Vertigo sufferers usually complain of the room spinning associated with certain head movements such as getting out of bed, looking up and bending down. BPPV can be diagnosed clinically from history and examination and does not require any investigations. BPPV can be effectively treated at the bedside by using one of the Canalith repositioning maneuvers (particle repositioning maneuvers). This treatment has been proven to be effective in randomised controlled trials and carries minimal risks. The common complications during the procedure include nausea, vomiting and vertigo. There are no absolute contraindications. BPPV can resolve spontaneously but symptoms may last for weeks in most patients, to years in others. Failure to respond to physical maneuvers and an unusual pattern of nystagmus may suggest a central pathology. Diagnostic strategies and physical manoeuvres are described in this narrative review. Future directions and recommendations also discussed.

Keywords: dizziness, BPPV, Epley, Dix-Hallpike, nystagmus, vertigo

ملخص

دوار الوضعة الانتيابي الحميد (BPPV) حالة مرضية شائعة يعالجها أطباء الطوارئ. ويشكو المصابون بهذا المرض من الشعور بدوران الغرفة عند تحريك الرأس في أوضاع معينة، مثل النهوض من السرير، والنظر لأعلى، والانحناء لأسفل. يعتمد تشخيص دوار الوضعة الانتيابي الحميد (BPPV) سريريًا على التاريخ المرضي للمريض أو الفحص العام دون الحاجة إلى إجراء فحص دقيق. ويمكن معالجة BPPV علاجًا فعالاً بجلسات سريرية يقوم فيها الطبيب باستخدام إحدى مناورات (تمارين) العلاج البدني (مناورات تصحيح وضع الجسميات). وقد أثبت هذا العلاج فعاليته في تجارب مراقبة عشوائية ولا ينطوي على مخاطر تذكر. ومن المضاعفات الشائعة أثناء إجراء هذه المناورات الغثيان، والتقيؤ، والدوار. وليس هناك موانع استعمال مطلقة. وقد يشفى BPPV تلقائيًا دون علاج ولكن تظل أعراضه من أسابيع عند معظم المرضى إلى سنين عند آخرين. ولكن في حالة عدم الاستجابة للمناورات الطبية وحدثت حركات غير المنضبطة للعين "الرأرأة"، فإن ذلك يدل على وجود أحد الأمراض المركزية. يتناول هذا الاستعراض المفصل وصفًا للاستراتيجيات التشخيصية والمناورات البدنية، كما يناقش أيضًا التوجهات المستقبلية ويقدم التوصيات.

¹Emergency Department, Hamad General Hospital, Doha, Qatar

²Emergency Department, Bronglais General Hospital, Aberystwyth, UK

*Email: khalidbashir1@btinternet.com

INTRODUCTION

Benign paroxysmal positional vertigo (BPPV) is defined as a spinning sensation by changes in the head relative to gravity. BPPV is the most common cause of vertigo. It can occur spontaneously in the 50-70 year age group. In younger ages the usual underlying cause is trauma. Almost 5.6 million Americans attend the hospital with complaints of dizziness every year, and 17 to 42 percent of these are ultimately diagnosed with BPPV.¹⁻³

Vertigo and nystagmus can have central (brainstem and cerebellum) or peripheral causes. It is important to differentiate between these two as the central cause will require investigation. The nystagmus due to central cause usually persists as long as the head is kept in the provoking position however, the nystagmus due to vestibular cause is always transient. In addition to the direction of nystagmus, its latency and fatigability may strongly suggest a peripheral vestibular cause of vertigo and does not usually require any investigations. Clinical features such as headache, visual symptoms, speech disturbance and weakness would all suggest a central cause. In one study, a central cause was found in cases of treatment failure for BPPV in 3 percent of cases. A central cause should be sought if the clinical features of BPPV are atypical or refractory to treatment.⁴

It has been known for BPPV patients to wait months or years for adequate treatment and to receive inappropriate medications such as vestibular sedatives and unnecessary diagnostic tests.⁵ In one study, 9 percent of elderly patients who were undergoing assessment for non-balance related problems were found to have undiagnosed BPPV. Older patients with BPPV may experience a greater incidence of falls which may cause injuries such as fractures, secondary brain injuries and may lead to permanent disability and increased care costs due to hospital visits and nursing home admissions.⁶

BPPV is the most common cause of peripheral vertigo responsible for almost 50 percent of patients with peripheral vestibular dysfunction. Misdiagnosis of BPPV can incur unnecessary costs, and one American study estimated that US\$2,000 per patient had been spent on consultations, laboratory tests and scans.^{7,8} BPPV effects the quality of life of the sufferers and it is usually restored after successful treatment by physical maneuvers.⁹

PATHOPHYSIOLOGY

The inner ear consists of snail-shell like structures called cochlea, and semicircular canals [Fig 1]. The cochlea is concerned with hearing and semicircular canals help to control balance and posture. There are three semicircular canals (anterior, posterior and lateral) and they are roughly at right angles to each other. Inside these bony canals, there is a system of narrow channels which contain fluid

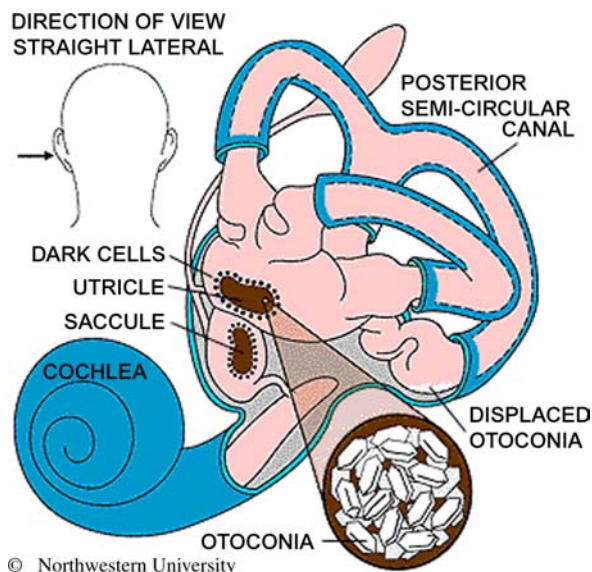


Figure 1. Anatomy of the left inner ear showing displaced otoconia from the utricle and saccule to the posterior semicircular canal (with permission from Hain, TC. <http://www.dizziness-and-hearing.com>. 7th February 2014 <http://www.dizziness-and-balance.com/images/bppv-otoconia-cd.gif>)

called endolymph. The movement of endolymph in the semicircular canals helps with the rotational balance i.e., head movements including side to side, forward, backwards and up and down. The semicircular canals are connected to the cochlea through a large fluid filled compartment called the vestibule. The vestibule contains the utricle and saccule. The vestibulocochlear nerve which arises from inner ear to the brain transmits information about balance and hearing to the brain.

The underlying cause of BPPV is believed to be the presence of calcium carbonate crystals in the semicircular canals, in particular the posterior semicircular canal.¹⁰ These crystals are understood to have migrated from the utricle [Fig 1]. The crystals in the canal cause abnormal deflection of the canal receptor, the cupula, resulting in an illusion of movement. The canalith repositioning maneuvers (CRM) help to move these crystals out of the semicircular canals back to the utricle to provide relief of vertigo symptoms. In spite of being a common medical problem, BPPV is still underdiagnosed or misdiagnosed by clinicians.¹¹

The posterior semicircular canal has been found to have otoconia in 85-95 percent of patients as compared to the horizontal canal. Approximately 85 percent are unilateral, and in 8 percent both posterior canals are involved. The horizontal canal is affected in about 5 percent of cases and involvement of the anterior canal is rare. In 1992, free floating particles were identified in the posterior semicircular canals during operative procedures.¹²⁻¹⁵ This finding is in favour of canalithiasis theory regarding causation of BPPV.

In most cases aetiology remains unknown however, various conditions that can predispose to BPPV include head injury, meniere's disease, acute labyrinthitis, postoperative ear, facial or brain surgery, and infections of the inner ear.^{8,16}

CLINICAL FEATURES

The earliest description of symptoms of BPPV has been attributed to Dr Robert Barany who in 1921 reported a case of a 27-year-old patient with vertigo induced by various positions. He also described it as a disorder of the otolith organs.¹⁷ Dix and Hallpike in 1952 described the symptomatology of BPPV in detail, based on their experience of treating 100 patients. They called this "positional nystagmus of the benign positional type". The commonly used diagnostic test called Dix-Hallpike test is based on re-production of these symptoms during various head positions.

In the 1960s, Harold Schukmecht confirmed the presence of small masses through basophilic staining of the posterior semicircular canals in patients with the diagnosis of BPPV.¹⁸

In 1979 Hall et al., and in 1993 John Epley explained all the symptoms of BPPV based on the presence of free floating particles in the semicircular canals. This theory is called "cupulolithiasis" and is still the most widely accepted explanation. Based on the cupulolithiasis theory, various successful treatment such as Epley and other Canalith repositioning maneuvers are being used throughout the world.^{13,19-21}

Patients usually complain of recurrent episodes of vertigo which can last for months. These episodes are provoked by various head movements such as looking up, bending down or rolling over in bed. These attacks may be associated with nausea and vomiting.

Patients with BPPV typically have no other neurologic complaints, in contrast to those with central causes of vertigo. Some patients have evidence of prior inner ear damage. Approximately half of patients complain of imbalance between attacks, even after successful treatment.^{8,22}

Some patients may develop anxiety episodes mainly due to fear of symptoms returning. These symptoms may have implications on certain jobs such as drivers, underwater divers and machinery operators as sudden vertigo attacks may endanger their life.

Medications are commonly given to vertigo sufferers to improve the spinning sensation and to control nausea and vomiting. The American Academies of Neurology and Otolaryngology-Head and Neck Surgery do not recommend routine use of medications such as antihistamines and benzodiazepines for the treatment of BPPV.²³ There is no evidence to suggest that these medications are effective or provide alternative treatment to Canalith repositioning maneuvers.²⁴⁻²⁷

The diagnosis of posterior canal BPPV is made after performance of the Dix-Hallpike maneuver [Fig 2]. During this maneuver, the following are the usual findings:

- Recurrence of vertigo symptoms
- Vertigo and nystagmus usually appears after a latent period of a few seconds
- The nystagmus is rotatory with the fast component towards the undermost ear

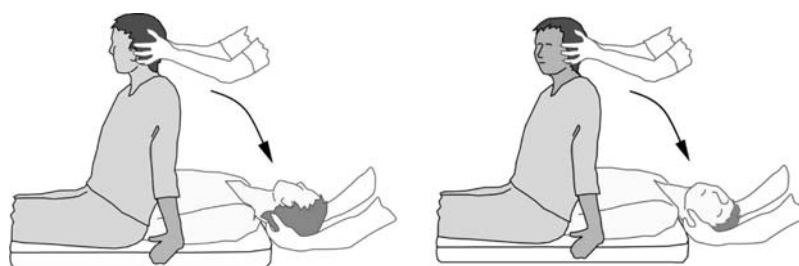


Figure 2. Dix-Hallpike maneuver

- When the patient sits up the nystagmus will beat in the opposite direction
- The intensity and duration of nystagmus decreases with repetition of this maneuver.²⁸

The diagnosis of lateral canal pathology is made by supine roll test. During this test, there is usually a horizontal nystagmus with the fast phase towards the ear being tested. This test can be performed in the outpatient clinic [Fig 3].

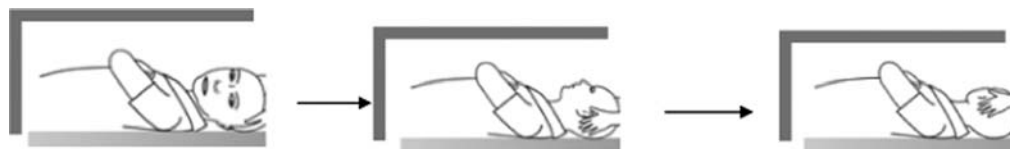

Figure 3. Supine roll test starting from the left side. [modified with permission from Hornibrook J, J Otolaryngology 2011. New Zealand].

TREATMENT

Treatment for BPPV is by returning or “repositioning” the detached otoconia back to the utricle. The commonly used techniques are the Epley Canalith Repositioning Procedure [Fig 4] and the Semont liberatory maneuver [Fig 5]^{21,29,30}.

The Epley maneuver starts with the patient sitting up and the head being turned towards the effected side, right side in Figure 4. The patient is reclined with the head overhanging the bed or pillow. In this reclined position, the head is turned towards the left. The head is turned further left as the patient is

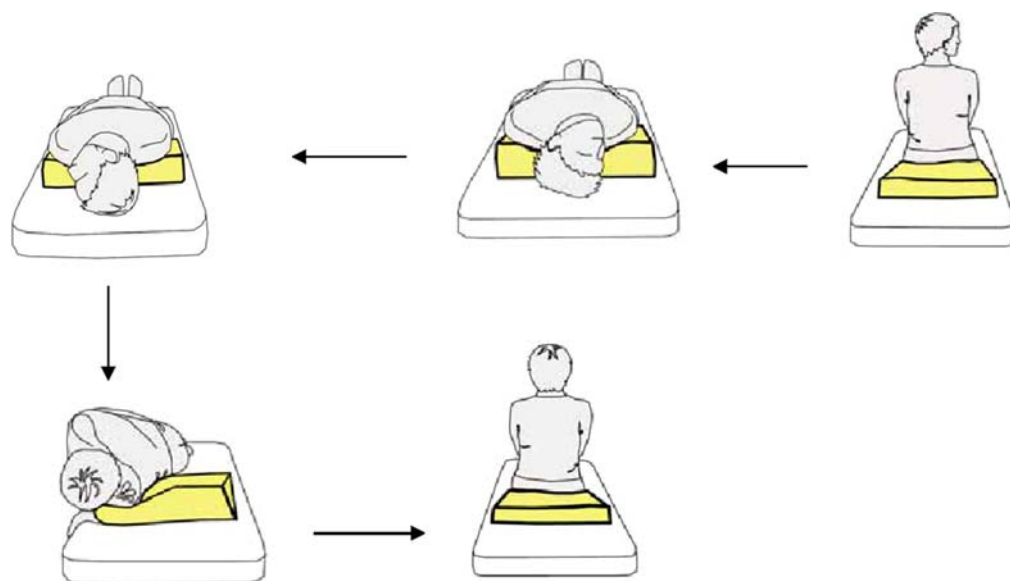


Figure 4. Modified Epley maneuver for treating right sided BPPV.

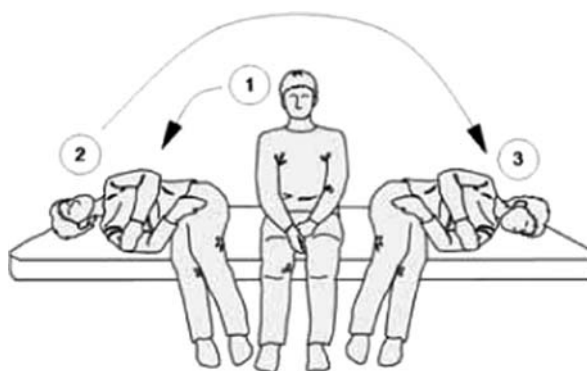

Figure 5. Semont's maneuver for treating right sided BPPV.

looking towards the floor. Finally, the patient is sat upright with the neck flexed. Each position lasts for 30 seconds.

Semont's maneuver starts with the patient sitting straight up on the examination table, the head is turned away from the "bad side". The head is first lowered to the side causing the vertigo. Then lying down, the patient looks up at the ceiling. This position is held for approximately 2-3 minutes. The patient is then quickly moved to the opposite side without stopping in the upright middle position. Again, this position lasts for 2-3 minutes and then finally in the upright position for 2-3 minutes.

The lateral or horizontal canal is less commonly involved and the maneuver that has been used to treat lateral canal BPPV is, the roll maneuver (Lempert maneuver or barbecue roll maneuver). This maneuver is performed by rolling the patient 360° in a few steps.^{31,32}

Anterior canal BPPV is rare, and symptoms may improve by performing the maneuvers recommended for the posterior canal. One study of 14 patients with anterior canal BPPV showed resolution of symptoms following the posterior canal maneuver.³³

POSTURAL RESTRICTIONS AFTER CANALITH REPOSITIONING MANEUVERS

Over the past two to three decades, BPPV patients were advised on the following postural restrictions, to maintain an upright posture for 1-2 days after the particle repositioning maneuvers, to avoid sleeping in a bed and to sleep in a chair instead and to avoid any bending over and looking upwards. Some physicians also used to recommend a soft collar to help patients to adhere to these instructions. Patients were also instructed to avoid sleeping on the affected ear for several nights. The rationale was to prevent the crystals re-entering the semicircular canals.

Some recent studies have shown that these restrictions are not necessary for recovery of BPPV.^{34,35} However, there is a systematic review in the Cochrane Library which concludes that the postural restrictions have significant (though clinically small) effect on recovery.³⁶ As the restrictions are easy to comply with and have no side effects, they should be discussed with the patient.

SURGICAL TREATMENT

In rare intractable cases, surgical treatment is considered as a last resort. Surgical management includes posterior semicircular occlusion (plugging) and transection of the ampullary nerve supplying the posterior semicircular canal. Both procedures are associated with complications such as disequilibrium and hearing loss.^{23,37-40}

FUTURE DIRECTIONS

Current evidence suggests that CRM improves symptoms in BPPV sufferers. This is based on the theory of free floating crystals in the semicircular canals. However, it is not clear as to why many patients get better without treatment. The exact pathophysiology is still not well understood, partly due to inability to visualize the inner structure of the semicircular canals in detail. There is need for robust scientific studies to explore this condition in more detail which may help in defining clear understanding about causation and effective treatments to prevent recurrences.^{41,42}

RECOMMENDATIONS

The following are recommendations by the American Academy of Otolaryngology-Head and Neck Surgery in the management of patients with BPPV:

1. A physician should diagnose posterior semicircular canal BPPV with symptoms of vertigo being associated with positive Dix-Hallpike test. These patients should be treated by one of the Canalith repositioning maneuvers
2. A physician should perform a supine roll test if there is history suggestive of BPPV and there is negative Dix-Hallpike test. Patients with positive supine roll test should be treated by one of the Canalith repositioning maneuvers
3. All above patients should be reassessed within one month of the physical maneuvers.
4. A physician should differentiate BPPV from other central causes of imbalance, and vertigo
5. A physician should investigate further only if there is treatment failure
6. There is no need for routine radiographic imaging in patients with history compatible with BPPV. However, if there is treatment failure or atypical symptoms then imaging may be needed
7. There is no need to treat BPPV routinely with medications such as antihistamines and benzodiazepines
8. A physician should counsel patients with a history of BPPV on their safety, recurrence and follow up.²³

REFERENCES

- [1] Schappert SM. National Ambulatory Medical Care Survey: 1989 summary. *Vital Health Stat.* 1992;13:1–80.
- [2] Katsarkas A. Benign paroxysmal positional vertigo (BPPV): idiopathic versus post-traumatic. *Acta Otolaryngol.* 1999;119:745–749.
- [3] Hanley K, O'Dowd T, Considine N. A systematic review of vertigo in primary care. *Br J Gen Pract.* 2001;51:666–671.
- [4] Smouha EE, Roussos C. Atypical forms of paroxysmal positional nystagmus. *Ear Nose Throat J.* 1995;74:649–656.
- [5] Fife D, FitzGerald JE. Do patients with benign paroxysmal positional vertigo receive prompt treatment? Analysis of waiting times and human and financial costs associated with current practice. *Int J Audiol.* 2005;44:50–57.
- [6] Oghalai JS, Manolidis S, Barth JL, Stewart MG, Jenkins HA. Unrecognized benign paroxysmal positional vertigo in elderly patients. *Otolaryngol Head Neck Surg.* 2000;122:630–634.
- [7] Li JC, Li CJ, Epley J, Weinberg L. Cost-effective management of benign positional vertigo using canalith repositioning. *Otolaryngol Head Neck Surg.* 2000;122:334.
- [8] von Brevern M, Radtke A, Lezius F, Feldmann M, Ziese T, Lempert T, Neuhauser H. Epidemiology of benign paroxysmal positional vertigo: A population based study. *J Neurol Neurosurg Psychiatry.* 2007;78:710–715.
- [9] Lopez-Escamez JA, Gamiz MJ, Fernandez-Perez A, Gomez-Finana M. Long-term outcome and health-related quality of life in benign paroxysmal positional vertigo. *Eur Arch Otorhinolaryngol.* 2005;262:507–511.
- [10] Hall SF, Ruby RR, McClure JA. The mechanism of benign paroxysmal vertigo. *J Otolaryngol.* 1979;8:151.
- [11] von Brevern M, Lezius F, Tiel-Wilck K, Radtke A, Lempert T. Benign paroxysmal positional vertigo: current status of medical management. *Otolaryngol Head Neck Surg.* 2004;130:381–382, 60.
- [12] Parnes LS, Agrawal SK, Atlas J. Diagnosis and management of benign paroxysmal positional vertigo (BPPV). *CMAJ.* 2003;169:681–693.
- [13] Parnes LS, McClure JA. Free-floating endolymph particles: a new operative finding during posterior semicircular canal occlusion. *Laryngoscope.* 1992;102:988–992.
- [14] Lempert T, Wolsley C, Davies R, Gresty MA, Bronstein AM. Three hundred sixty-degree rotation of the posterior semicircular canal for treatment of benign positional vertigo: a placebo-controlled trial. *Neurology.* 1997;49:729–733.
- [15] Honrubia V, Baloh RW, Harris MR, Jacobson KM. Paroxysmal positional vertigo syndrome. *Am J Otol.* 1999;20:465–470.
- [16] Lee NH, Ban JH, Lee KC, Kim SM. Benign paroxysmal positional vertigo secondary to inner ear disease. *Otolaryngol Head Neck Surg.* 2010;143:413.
- [17] Barany R. Diagnose von krankheitsersch-eingungen im merische deotolithenapparates. *Acta Otolaryngol.* 1921;2:434–437.
- [18] Schuknecht HF. Positional vertigo. Clinical and experimental observations. *Transactions of the American Academy of Ophthalmology and Otolaryngol.* 1962;66:319–331.
- [19] Hall SF, Ruby RR, McClure JA. The mechanics of benign positional vertigo. *Journal of Otolaryngology.* 1979;8:151–158.
- [20] Epley JM. Benign paroxysmal vertigo (canalithiasis): diagnosis and non-surgical treatment. In: Arenber IK, ed. *Dizziness and Balance Disorders.* Amsterdam, The Netherlands: Kugler; 1993:545–559.
- [21] Semont A, Freyss G, Vitte E. Curing the BPPV with a liberatory maneuver. *Adv Otorhinolaryngol.* 1988;42:290–293.
- [22] Brandt T, Daroff RB. Physical therapy for benign paroxysmal positional vertigo. *Arch Otolaryngol.* 1980;106:484.
- [23] Parnes LS, McClure JA. Posterior semicircular canal occlusion in the normal hearing ear. *Otolaryngol Head Neck Surg.* 1991;104:52–57.
- [24] Frohman EM, Kramer PD, Dewey RB, Kramer L, Frohman TC. Benign paroxysmal positioning vertigo in multiple sclerosis: diagnosis pathophysiology and therapeutic techniques. *Mult Scler.* 2003;9:250–255.
- [25] Hain TC, Uddin M. Pharmacological treatment of vertigo. *CNS Drugs.* 2003;17:85–100.
- [26] Hain TC, Yacovino D. Pharmacologic treatment of persons with dizziness. *Neurol Clin.* 2005;23:831–853, vii.

- [27] Fujino A, Tokumasu K, Yosio S, Naganuma H, Yoneda S, Nakamura K. Vestibular training for benign paroxysmal positional vertigo. Its efficacy in comparison with antivertigo drugs. *Arch Otolaryngol Head Neck Surg.* 1994;120:497–504.
- [28] Furman JM, Cass SP. Benign paroxysmal positional vertigo. *N Engl J Med.* 1999;341:1590.
- [29] Alcione BP, Nunes S, Fernando M. Effect of Epley's maneuver on the quality of life of paroxysmal positional benign vertigo patients. *Braz J otorhinolaryngol.* 2010;76(6):704–708.
- [30] Epley JM. The canalith repositioning procedure: for treatment of benign paroxysmal positional vertigo. *Otolaryngol Head Neck Surg.* Sep 1992;107(3):399–404.
- [31] White JA, Coale KD, Catalano PJ, Oas JG. Diagnosis and management of lateral semicircular canal benign paroxysmal positional vertigo. *Otolaryngol Head Neck Surg.* 2005;133:278–284.
- [32] Prokopakis EP, Chimona T, Tsagournisakis M, Christodoulou P, Hirsch BE, Lachanas VA, Helidonis ES, Plaitakis A, Velegarakis GA. Benign paroxysmal positional vertigo: 10-year experience in treating 592 patients with canalith repositioning procedure. *Laryngoscope.* 2005;115:1667–1671.
- [33] Imai T, Takeda N, Ito M, Inohara H. Natural course of positional vertigo in patients with apogeotropic variant of horizontal canal benign paroxysmal positional vertigo. *Auris Nasus Larynx.* 2011;38:2.
- [34] Massoud EA, Ireland DJ. Post-treatment instructions in the nonsurgical management of benign paroxysmal positional vertigo. *J Otolaryngol.* 1996;25:121–125.
- [35] Roberts RA, Gans RE, DeBoodt JL, Lister JJ. Treatment of benign paroxysmal positional vertigo: necessity of post maneuver patient restrictions. *J Am Acad Audiol.* 2005;16:357–366.
- [36] Hunt WT, Zimmermann EF, Hilton MP. Modifications of the Epley (canalith repositioning) manoeuvre for posterior canal benign paroxysmal positional vertigo (BPPV). <http://www.ncbi.nlm.nih.gov/pubmed/22513962>
- [37] Gacek RR. Further observations on posterior ampullary nerve transection for positional vertigo. *Ann Otol Rhinol Laryngol.* 1978;87:3005.
- [38] Gacek RR. Singular neurectomy update. *Ann Otol Rhinol Laryngol.* 1982;91:469–473, vertigo. *Acta Otolaryngol* 1995;115:154-7.
- [39] Parnes LS, McClure JA. Posterior semicircular canal occlusion for intractable benign paroxysmal positional vertigo. *Ann Otol Rhinol Laryngol.* 1990;99:330–334.
- [40] Parnes LS. Update on posterior canal occlusion for benign paroxysmal positional vertigo. *Otolaryngol Clin North Am.* 1996;29:333–342.
- [41] Bhattacharyya N, Baugh RF, Orvidas L, Barrs D, Bronston LJ, Cass S, Chalian AA, Desmond AL, Earll JM, Fife TD, Fuller DC, Judge JO, Mann NR, Rosenfeld RM, Schuring LT, Steiner RW, Whitney SL, Haidari J. American Academy of Otolaryngology-Head and Neck Surgery Foundation. Clinical practice guideline: Benign paroxysmal positional vertigo. *Otolaryngology-Head and Neck Surgery.* 2008;139:S47–S81.
- [42] Zucca G, Valli S, Valli P, Perin P, Mira E. Why do benign paroxysmal positional vertigo episodes recover spontaneously? *Journal of Vestibular Research: Equilibrium and Orientation.* 1998;8(4):325–329.