

RESEARCH PAPER

# Surgical management of benign tracheal stenosis in Basrah

Muayyad M. Almodhafer, Fouzi A.A. Al-Hassani, Abdul-Khalik Z. Benyan

Address for Correspondence:

**Fouzi A. A. Al-Hassani**

Basra Teaching Hospital, Basra, Iraq

Email: fouzi.76@hotmail.com

<http://dx.doi.org/10.5339/qmj.2013.9>

Submitted: 17 June 2013

Accepted: 19 June 2013

© 2013 Almodhafer, Al-Hassani, Benyan, licensee Bloomsbury Qatar Foundation Journals. This is an open access article distributed under the terms of the Creative Commons Attribution license CC BY 3.0, which permits unrestricted use, distribution and reproduction in any medium, provided the original work is properly cited.

Cite this article as: Almodhafer MM, Al-Hassani FAA, Benyan A-KZ. Surgical management of benign tracheal stenosis in Basrah, Qatar Medical Journal 2013;9 <http://dx.doi.org/10.5339/qmj.2013.9>

 **QSCIENCE.com**  
Member of Qatar Foundation

## ABSTRACT

**Background:** Tracheal stenosis is more frequent as a result of wide-spread use of endotracheal intubation and tracheostomy. Resection and tracheal reconstruction remain the treatment of choice in benign tracheal stenosis.

**Objectives:** To report our experience in Basra and to identify the result of anastomosis after tracheal resection and management of those patients preoperatively and postoperatively.

**Methodology:** A descriptive study of sixteen patients (aged 11 – 28 years, 10 male and 6 female) with tracheal stenosis who underwent tracheal resection and reconstruction in Basrah thoracic unit (Basra teaching hospital) from January 2008 to January 2011.

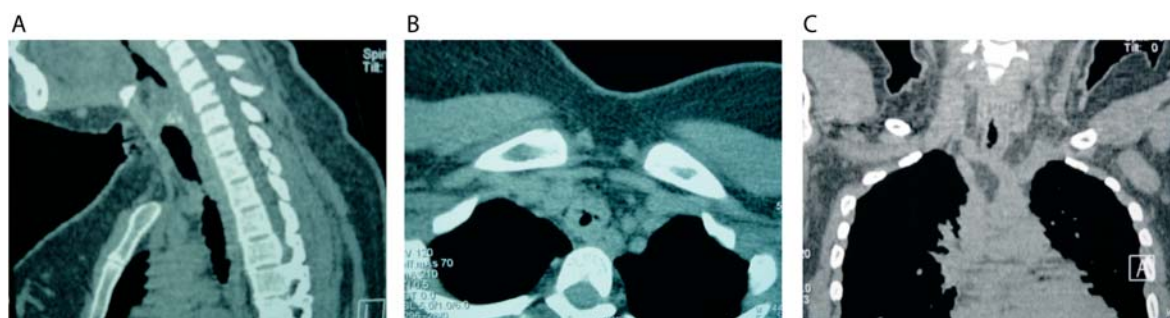
**Results:** The result was excellent in 62.5%, good in 25%, and satisfactory in 12.5%. Postoperative complication occurred in 25% and treated successfully with no mortality. Follow-up was every 3 months for an average of 3.6 years.

**Conclusion:** Resection and tracheal reconstruction is the treatment of choice in benign tracheal stenosis and achieved excellent results in management of the patients.

## INTRODUCTION

Tracheal stenosis is still observed due to increasing number of patients having tracheostomy and prolonged endotracheal intubation<sup>(1-3)</sup> for respiratory support which are the main causes of stenosis (up to 67%).<sup>(1,2,4)</sup> Other causes of tracheal stenosis are less common; they may result from laryngeal or tracheal trauma, chemical burn and radiotherapy.

Many procedures have been devoted in recent years to solve this problem and to repair tracheal stenosis



**Figure 1.** Computed tomography shows post-intubational cervical tracheal stenosis in 28 years old female A: sagittal section. B: transverse section. C: coronal section.

like airway transplantation, allograft with temporary or permanent stent, balloon dilatation and stent.<sup>(5,6)</sup>

Despite the different approaches developed recently, tracheal resection and end-to-end anastomosis of the trachea is an effective treatment for stenosis with high success rates.<sup>(3,7,8)</sup> The aim of this article is to report our experience of tracheal stenosis treatment in 16 patients in the period from January 2008 to January 2011 with an average follow-up period of 3.6 years.

## METHODOLOGY

Sixteen patients with progressive dyspnoea were reported during the period from January 2008 to January 2011, their ages ranged from 11 years to 28 years. There were 10 male and 6 female patients. The cause of dyspnoea was tracheal stenosis in all of them who had undergone endotracheal intubation or tracheostomy for respiratory resuscitation following trauma.

Full history was taken and complete physical examination was performed. The investigations requested were chest x-rays, C-T scan (sagittal and coronal sections) for both the neck and the chest to reveal the length, severity of stenosis and the status of the vocal cords (Figure 1a, b, c), delineates the airway below the stenosis which cannot be assessed by bronchoscopy and gives an idea on the cartilagenous support and the surrounding structures. Sputum was sent for bacteriological examination with culture and sensitivity test.

Pre-operative bronchoscopic examination of the larynx and the trachea was performed in all patients to determine the state of the tracheal mucosa, the vocal cords status and the distance up to the stenosis, and

for the assessment of the location and the length of the stenosis.

Cervical tracheal stenosis was in 12 patients (75%), and intrathoracic lesions were in 4 patients 25% (Figure 2). One of the cervical tracheal lesions was subglottic stenosis (7.2%) (Figure 3). Four patients received preoperative tracheostomies performed in other hospitals.

We used the grading system proposed by Ghorbani et al.,<sup>(9)</sup> which depends on three factors (diameter of stricture, type of stenosis and clinical symptoms) (Table 1); and we classified the patients according to that system and giving a score to each patient.

All patients received antibiotic and steroid inhalational therapy preoperatively for temporary palliative airways opening and preoperative bronchoscopic dilatations were attempted in some patients.



**Figure 2.** C-T scan shows post-intubational intrathoracic tracheal stenosis in 11 years old boy.

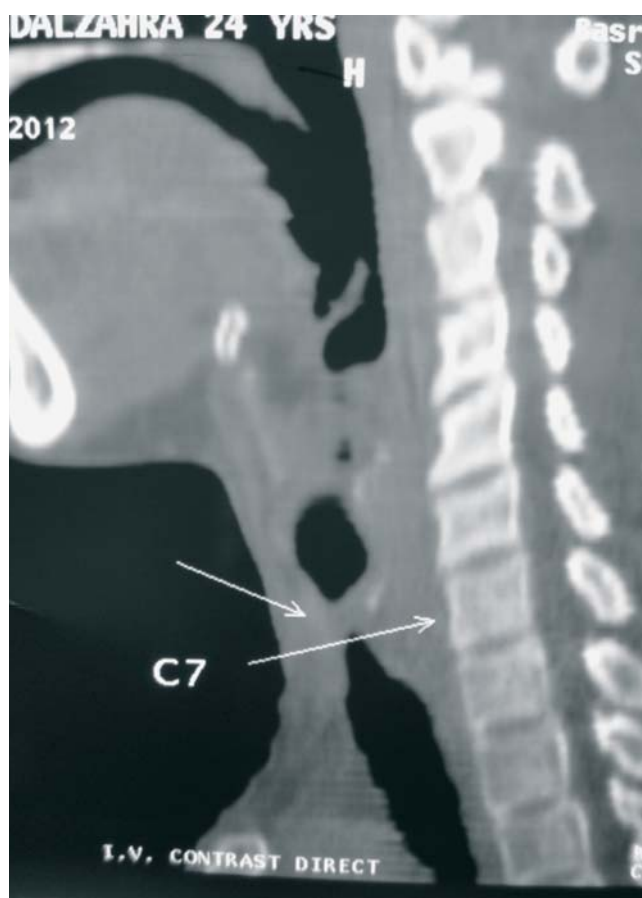


Figure 3. C-T scan for 24 years male with post-intubational subglottic tracheal stenosis.

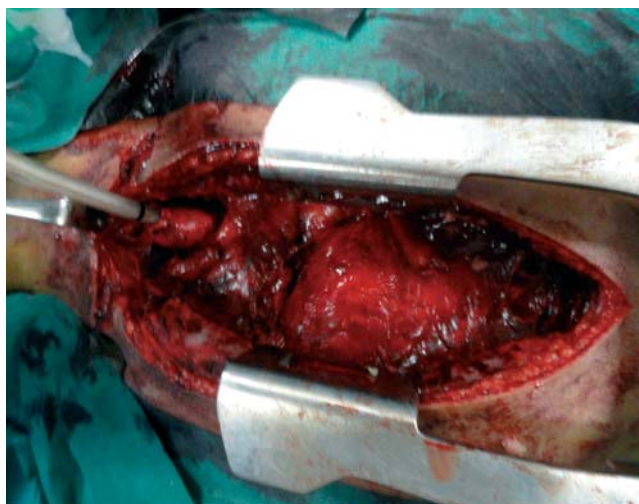
## SURGICAL TREATMENT

Complete excision of the stenotic lesion was performed; the operative approach was by cervical collar incision with sternal split in 11 patients and cervical collar incision with median sternotomy in the other 5 patients (Figure 4). The anterior and lateral surfaces of the trachea was exposed and carefully dissected close to the walls of the trachea to avoid injuries to the recurrent laryngeal nerves and blood supply. The dissection was extended up to the cricoid cartilage above and down to the carina below for better mobilization of the trachea. The resection was performed between the cartilaginous rings to allow anastomosis in a healthy area (Figure 5). End-to-end anastomosis was done using 4 interrupted sutures of 2–0 or 3–0 Vicryle for membranous part and 12–14 interrupted sutures for the cartilaginous part (Figure 6).

Ventilation was initially maintained by oro-pharyngeal endotracheal tube above the stenotic site. Ventilation was later maintained by cross-field endotracheal tube placed in the distal tracheal tract when resection of stenotic segment of the trachea was done and the tube was withdrawn. The tube was removed when the anastomosis completed and rhino-tracheal tube was placed in through the anastomosis and the suture knots were tied outside. In patients with pre-existing tracheostomies, the stoma was resected with the stenotic tract.

Table 1. A proposed grading system for post-intubation tracheal stenosis by Ghorbani et al.<sup>9</sup>

Factor	Description	Score
Diameter of stricture	Stenosis rate between 0–25%	0
	Stenosis rate between 26–50%	1
	Stenosis rate between 51–75%	2
	Stenosis rate between 76–90%	3
	Stenosis rate over 91%	4
Type of stenosis: was determined based on the type of tissue of the lesion	Granulation tissue	1
	Granulation tissue, fibrosis and inflammation	2
	Fibrosis	3
	Malacia	4
Clinical symptoms	Dyspnea only during intense activity	1
	Dyspnea during normal activity but physical examination was normal	2
	Long inhalation and exhalation but with no stridor or retraction	3
	Presence of stridor and retraction	4

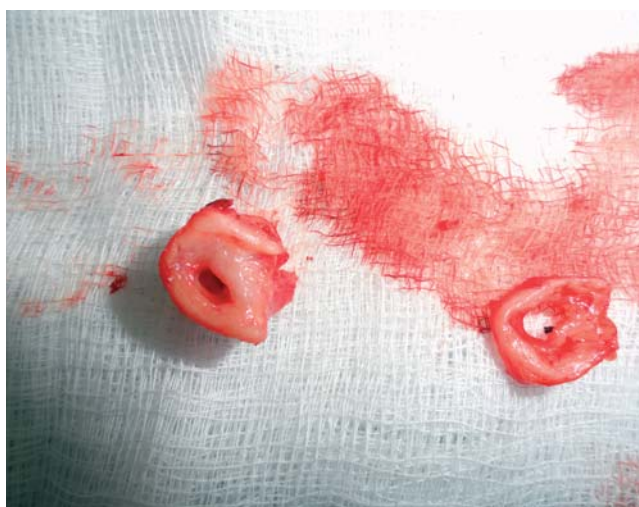

**Figure 4.** Photography shows collar incision and median sternotomy with armored endotracheal tube through tracheostomy opening.

The neck is flexed during tracheal anastomosis and heavy sutures were used post-operatively to tie the chin to the chest skin with neck in hyperflexion.

## RESULTS

The mean score obtained for all patients was 9.44 (range 9–11) (Table 2) and the surgical reconstruction performed in all 16 patients. The outcome of the patients and the state of their respiration were analyzed at discharge time from the hospital and at 3 months intervals. The result was classified as excellent, good, satisfactory and failure according to patient usual activities and phonation with

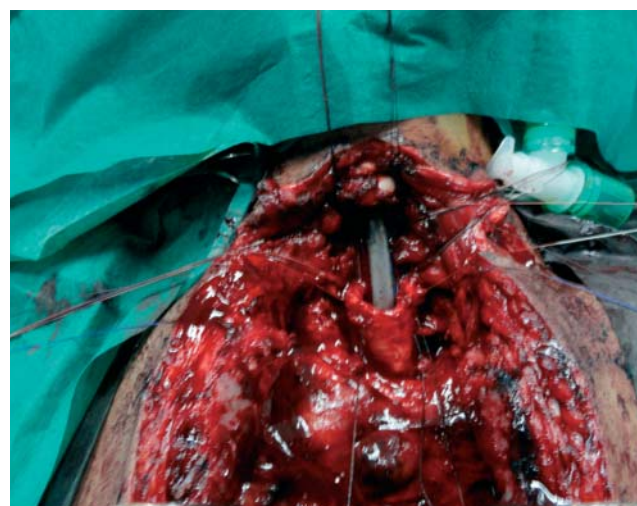

**Figure 5.** Stenosed segment of the trachea resected in two pieces.

bronchoscopic assessment of the size of the anastomosis site. The average length of follow-up in our patients was 3.6 years. The result was excellent in 10 patients (62.5%) as they were able to perform normal daily activities, and endoscopically the patency of airway was of 90–100%; in 4 patients (25%), the result was good as they did the usual daily activities normally with airway patency of 70–80%. Two patients (12.5%) had satisfactory result as they were able to perform daily activities but had dyspnoea on stress and exertion. No failures were in our series.

Post-operative complications occurred in 4 patients (25%), restenosis occurred in 1 patient (6.2%) who was treated successfully with bronchoscopy and dilatation using carrot head dilators. Superficial wound infection occurred in 2 patients (12.5%) and was dealt with by drainage, daily dressing and appropriate antibiotics. One patient (6.2%) had temporary vocal cords oedema that mandated reintubation and mechanical ventilation with heavy parental steroid therapy for 24 h and extubation was done successfully in the next day.

No mortality in our series; all patients were discharged at 15<sup>th</sup>–20<sup>th</sup> post-operative day. All patients had flexible endoscopic examination before discharge. Rigid bronchoscopic examination under general anesthesia was done on follow-up at 3 months and fiberoptic bronchoscopy was done every three months for two years of follow-up.



**Figure 6.** Photography shows several 2–0 Vicryle stay sutures between the proximal and distal part of the trachea after resection of stenotic part with rhinotracheal intubation through the anastomosis).

Table 2. Scores of 16 patients.

Patients	Diameter of stricture \ score	Type of stenosis \ score	Clinical symptoms \ score	Total
1	3	2	4	9
2	2	3	4	9
3	3	3	4	10
4	3	3	4	10
5	2	3	4	9
6	2	3	4	9
7	3	3	4	10
8	3	3	4	10
9	3	2	4	9
10	3	2	4	9
11	4	3	4	11
12	2	3	4	9
13	3	2	4	9
14	3	2	4	9
15	3	3	3	9
16	3	4	3	10

## DISCUSSION

The causes of tracheal stenosis in all our patients were post intubation and tracheostomy. This have been well established by many authors as a leading causes of tracheal stenosis.<sup>(3,8,10,11)</sup>

Pre-operative assessment had been done including full history, thorough physical examination, bronchoscopy and C-T scan to find the exact location of the stenosis, its length, the presence or absence of inflammation and oedema at the site of stenosis and its border. Rigid bronchoscopy was performed in all patients; and we agree with others that bronchoscopy is the best pre-operative diagnostic procedure to evaluate the state of tracheal stenosis.<sup>(3,12)</sup>

Pulmonary function tests are usually not necessary in the diagnostic workup of the patient, as they may provide an insight on the functional limitations of the patient.<sup>(13,14)</sup>

Computed tomography with saggital and coronal sections gave useful information about the stenosis. It delineates the airway below the stenosis, which cannot be assessed by bronchoscopy. It also gives an idea of the cartilagenous support and the surrounding structures, in spite that other authors suggest that it does not add further information to rigid bronchoscopy findings.<sup>(12,15)</sup>

The mean score obtained for all patients was 9.44 (range 9 – 11). This means that they had significant stenosis that requires surgical reconstruction. This is compatible with the grading system proposed by Ghorbani et al., who suggested that surgical treatments are required for every patient with a score over 8.5.<sup>(9)</sup>

In the surgical technique, we used the basic principles of the tracheal reconstruction introduced by authors with large experience.<sup>(3,4,6,10,12,16)</sup> These principles include avoidance of anastomosis tension, maintenance of tracheal blood supply and preservation of recurrent laryngeal nerve with careful and meticulous dissection and anastomosis. We adopted interrupted Vicryle sutures for anastomosis (2 – 0 or 3 – 0) in all patients.

Our results were excellent in 62.5%, good in 25% and satisfactory result in 12.5%, with no failure in our series. This remarkable result is due to the adoption of the suggestions by the expert authors.<sup>(3,12,17)</sup>

No major complication observed with our patients. One patient developed vocal cord oedema that was managed successfully by reintubation for 24 h. Two patients developed superficial wound infection, which was managed by conservative treatment (wound debridement, daily dressing and antibiotics) and achieved complete healing in both of them. One

patient developed restenosis a month after surgery; this was also managed successfully by bronchoscopic dilatation.

No adjuvant therapy (like local injection of mitomycin or other substances) was used post-operatively, because it not found in our locality and we have no experience with it.

In conclusion, laryngotracheal stenosis, despite all measures to avoid its occurrence, remains one of the serious problems following tracheostomies and endotracheal intubations.

According to our results, we confirm that surgery is the best way to treat the benign laryngotracheal stenosis.

## REFERENCES

1. Nouraei SAR, Ma E, Patel A, Howard DJ, Sandhu GS. Estimating the population incidence of adult post intubation laryngotracheal stenosis. *Clin Otolaryngol*. 2007;32:411 – 412.
2. Law JH, Barnhart K, Rowlett W, De La Rocha O, Lowenberg S. Increased frequency of obstructive airway abnormalities with long term tracheostomy. *Chest*. 1993;104:136 – 138.
3. Grillo HC, Dorahue DM, Mathisen DJ, Wain JC, Wright CD. Post intubation tracheal stenosis treatment and results. *J Thorac Cardiovasc Surg*. 1995;109:486 – 493.
4. Andrews MJ, Pearson FG. Incidence and pathogenesis of tracheal injury following cuffed tube tracheostomy with assisted ventilation: analysis of a two-year prospective study. *Ann Surg*. 1971;173:249 – 263.
5. Wurtz A, Porte H, Conti M, Desbodes J, Copin ML, Azorin J, Martinod E, Marquette CH. Tracheal replacement with aortic allograft. *N Engl J Med*. 2006;355:259 – 260.
6. Nashet SAM, Dormer C, Velly JF, Labrousse S, Courand L. Expanding wire stent in benign trachea bronchial disease, indication and complications. *Ann Thorac Surg*. 1992;54:937 – 940.
7. Pearson FG, Cooper JD, Nelems JM, Van Nostrand AWP. Primary tracheal anastomosis after resection of cricoid cartilage with preservation of recurrent laryngeal nerves. *J Thorac Cardiovasc Surg*. 1975;70:806 – 815.
8. Grillo HC. Primary reconstruction of airway after resection of subglottic laryngeal and tracheal stenosis. *Ann Thorac Surg*. 1982;33:2 – 12.
9. Ghorbani A, Abbasi Dezfouli A, Behgam Shadmehr M, Pejhan S, Reza Saghebi S, Ghare-Daghi Aba-saad, Farzanegan R, Jahanshahi N. A proposed grading system for post-intubation tracheal stenosis. *Tanafos*. 2012;11(3):10 – 14.
10. Couraud L, Jacques BJ, Velly JF. Surgical treatment of non tumoral stenosis of the upper airway. *Ann Thorac Surg*. 1995;60:250 – 260.
11. Cooper JD, Grillo HC. The evaluation of tracheal injury due to ventilator assistance through cuffed tubes; a pathologic study. *Ann Surg*. 1969;169:334 – 348.
12. Grillo HC, Donahue DM, Mathisen DJ, Wain JC, Whight CD. Post intubational tracheal stenosis, treatment and results. *J Thorac Cardiovasc Surg*. 1995;109:486 – 493.
13. Acres JC, Kryger MH. Clinical significance of pulmonary function tests: upper airway obstruction. *Chest* 1981 Aug;80(2):207 – 211.
14. Wassermann K, Koch A, Warschkow A, Mathen F, Müller-Ehmsen J, Eckel HE. Measuring in situ central airway resistance in patients with laryngotracheal stenosis. *Laryngoscope* 1999 Sep;109 (9):1516 – 1520.
15. Pradipta KP, Gupta AK. Management of laryngotracheal stenosis – our experience. *Indian J Otolaryngol Head Neck Surg*. 2009;61(4):306 – 312.
16. Grillo HC. Reconstruction of the trachea; experience in 100 consecutive cases. *Thorax* 1973;26:667 – 678.
17. Morcillo A, Wins R, Goñmez-Caro A, Paradela M, Molins L, Tarrazona V. Single staged laryngotracheal reconstruction of idiopathic tracheal stenosis. *Ann Thorac Surg*. 2013;95:433 – 439.